

**Arterial Lower Limb Duplex**Examined **27/12/2018 09:00**

Page 1 of 2

C Chan

Reference

Accession **CR-18-0067071**Patient **Glyn Morgan**NHS No **454 734 2334**D.O.B. **18/02/1949**Patient Ref **5250893****Reason** Stent**Outcome** Widely patent, Occlusion, Mild Disease**Right**

130

1.00

Brachial**Common Femoral**

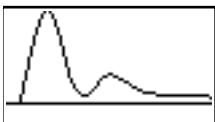
Good

High Thigh**Low Thigh****Popliteal**

Good

High Calf**Peroneal****Anterior Tibial**

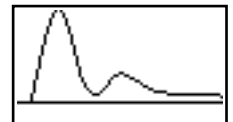
Good

Posterior Tibial**Dorsalis Pedis****Toe Pressure****Post Exercise****Left**

Good

140

1.08

**Notes**

LEFT LOWER LIMB ARTERIAL DUPLEX (previous SFA stent)

CFA, PFA origin - widely patent with mild disease, triphasic waveforms, PSV 129-139cm/s.

SFA - proximal to mid vessel is patent with mild disease and vessel calcification, triphasic waveforms, PSV 178-109cm/s. Stent noted in the mid to distal SFA and appears widely patent, good triphasic waveforms, PSV 106-119cm/s.

PopA - widely patent, with mild calcified disease, good triphasic waveforms, PSV 93-100cm/s.

TPT is patent. 3 run-off origins noted.

Assessed by **Sharifa Kiyegga**

Printed on 30/01/2019 at 5:24 pm

Checked by _____

**C Chan**

Reference

Accession **CR-18-0067071**

Patient **Glyn Morgan**
D.O.B. **18/02/1949**

NHS No **454 734 2334**
Patient Ref **5250893**

ATA - calcified but patent along length, triphasic to good monophasic waveforms at the ankle, PSV 151cm/s
PTA - heavily calcified. Proximal vessel appears patent with good biphasic waveforms. Mid to distal vessel appears occluded with no colour flow noted. Patent at the ankle with reduced monophasic waveforms, PSV 22cm/s.

RIGHT:

CFA - widely patent, triphasic waveforms, PSV 107cm/s.

ATA - patent at ankle, good monophasic waveforms, PSV 168cm/s.

PTA - patent at the ankle, slightly reduced monophasic waveforms, PSV 27cm/s.

Bilateral resting ABPI's are good/ within normal limits (Right - 1.08, Left - 1.0).

